PSNet
PATIENT SAFETY NETWORK

Don't Pick the PICC

July 1, 2018
McGill RL. Don't Pick the PICC. PSNet [internet]. 2018.
https://psnet.ahrq.gov/web-mm/dont-pick-picc

The Case

A 63-year-old man with diabetes mellitus complicated by retinopathy, neuropathy, and nephropathy; glaucoma; and stage IV chronic kidney disease was admitted to the hospital with an ulcer on the bottom of his right foot. Physical examination revealed a 2 cm clean-based ulcer below the fifth metatarsal head of the right foot. No surrounding swelling or erythema was present, but the ulcer could be probed to the underlying bone. An MRI was highly concerning for osteomyelitis, and a bone biopsy showed chronic inflammation with cultures positive for methicillin-sensitive *Staphylococcus aureus*. An infectious diseases consultant recommended therapy with 6 weeks of intravenous ceftriaxone to be given via outpatient parenteral antimicrobial therapy.

The interventional radiology team was consulted to place a peripherally inserted central catheter (PICC) line for antibiotic therapy. They attempted the placement multiple times in the right brachial vein but failed. The line was then successfully placed in the left brachial vein. The patient's nephrologist was not consulted prior to placing the PICC line. The patient was discharged and completed 6 weeks of antibiotics and wound care, with healing of the osteomyelitis and ulcer. The PICC line was then removed.

Five months later, the patient was seen by his nephrologist and was found to have worsening renal function and hyperphosphatemia. Dialysis access planning was initiated, but unfortunately, when the patient was evaluated by a vascular surgeon, he was found not be a candidate for arteriovenous fistula placement (the safest and most effective form of dialysis access). He was thought to have poor vein quality due to the many venipuncture attempts during the PICC line placements several months previously. Instead of a fistula, the patient had an arteriovenous graft placed, and dialysis was initiated 3 months later.

The patient's nephrologist referred the case to interventional radiology and hospital medicine for review given the preventable complication. The groups collaborated to develop a protocol to review renal function in patients who have requests for PICC lines, with nephrology approval required before any long-term venous access can be placed in patients with stage III–V chronic kidney disease.

The Commentary

Commentary by Rita L. McGill, MD, MS

Hemodialysis has been available to treat chronic kidney failure for 60 years, during which the ability to achieve durable vascular access via a fistula composed of native vessels has proven to be one of the most important determinants of patient outcomes. Increasing fistula placement in hemodialysis patients has been a national public health priority, included in both Healthy People 2010 and 2020.(1)

Peripherally inserted central catheters (PICCs), invented for the sole purpose of administering hypertonic parenteral nutrition solutions that normally required central venous catheters (CVCs), were first described in 1975.(2) Over the next 20 years, vascular ultrasound emerged as the optimal way to guide proper placement of PICC, and mobile teams of specialized nurses with portable ultrasound have become an efficient way to provide PICCs to inpatients.(3,4) Over the same period, indications for PICC have expanded well beyond parenteral nutrition, PICCs are kept in place for increasing periods of time, and PICC use has migrated into the home care setting, allowing prolonged intravenous therapy to be provided to patients outside the hospital.(5,6)

Popular with physicians, nurses, and patients, PICCs are more comfortable than CVCs, eliminate some of their dangerous complications (e.g., pneumothorax and central arterial puncture), and resemble a conventional peripheral intravenous line. Once placed (Figure 1), they obviate the need for peripheral venipuncture. Unfortunately, like CVCs, PICCs are undeniably associated with multiple complications. These include thrombophlebitis, deep venous thrombosis, and catheter-associated bacteremia, with secondary complications of sepsis, endocarditis, and osteomyelitis.(7)

Patients with kidney disease often have underlying systemic diseases such as diabetes, which put them at risk for hospitalizations and PICC placements. In a medium-sized teaching hospital, PICCs were present in 30% of inpatients with chronic kidney disease. The reasons for placement were poorly defined (such as convenience) in 49% of patients with PICCs.(8) Unfortunately, PICCs damage critical veins that kidney patients need for future dialysis fistulas. In a retrospective series at Mayo Clinic, a history of PICC placement was associated with three times greater likelihood of that individual being unable to achieve a working fistula.(9) When fistulas cannot be obtained, with or without the use of prosthetic graft material, hemodialysis patients depend upon a series of central dialysis catheters and have greatly increased hazards of sepsis and death.(10) Among a cohort of nearly 34,000 patients initiating hemodialysis with central venous dialysis catheters, 1 in 8 had a previous exposure to PICC.(11) These patients had increased mortality and decreased likelihood of achieving any fistula or graft.(11)

The patient in this illustrative case had complicated diabetes with stage 4 nephropathy, a situation with a 20% to 50% risk of kidney failure over the next 2 years, and near-certainty of kidney failure over 5 years.(12) If the patient's life expectancy was longer than these timeframes, the protection of his veins should have been a very high priority. His nephrologist understood the guidelines for patients with chronic kidney disease (13) but was not part of his inpatient care team at that time. Vein protection therefore needs to be part of the care process early on, while hospitalists and other physicians are directing medical care. Requiring assent from a nephrologist is one approach, but a more reliable alternative is to automatically avoid PICC placement in patients with a certain level of kidney function.

Peripherally inserted central catheter complications are more likely when the ratio of catheter diameter to vein diameter increases.(14,15) Inserting a 3–5 French catheter such as a PICC in an internal or external jugular vein is therefore less likely to cause vein damage than if the same device was installed in a narrower vein in the upper arm. Hemodialysis fistulas (Figure 2) are constructed from the connection of the radial or brachial arteries to an intact cephalic or basilica vein, and they require an unobstructed venous pathway for blood to return to the central circulation. Therefore, the use of a jugular vein spares peripheral veins that might be crucial for future fistulas.(16) Initiatives at the University of Michigan, the University of Pennsylvania, and the Mayo Clinic have shown that automatic referral of high-risk kidney patients for small-bore central catheters can reduce or eradicate inappropriate PICCs.(14-16) This approach requires planning to ensure the availability of resources to place small-bore central catheters in a timely fashion and to allow staff to develop comfort with using such devices.

Another important recommendation for individual physicians is to carefully examine the indications for PICCs and to resist the tendency to place an inappropriate PICC as a convenience or a path of least resistance. The Michigan Appropriateness Guide for Intravenous Catheters (MAGIC) helps practitioners assess vascular access options and choose the wisest options for their patients.(17) Hospitalist services are studying and refining the application of these guidelines (18), which also have the benefit of protecting future hemodialysis patients for whom the risk of kidney failure is not yet readily apparent.

Aside from injection drug users, vein depletion in the upper extremity is caused by health care–associated venipuncture. Medical conditions (such as diabetes) that cause kidney failure often require extensive health care with cumulative exposure to venous injury. Due to their placement in critical veins and extended dwell times, PICCs are problematic. This patient's PICC was placed in an arm that was subsequently deemed to be too damaged to permit a dialysis fistula. The contralateral veins were already unusable by the time of the PICC, suggesting repeated vein injuries in both arms over time. Protocols that preserve the veins of patients at risk for future dialysis can reduce adverse events related to the use of hemodialysis catheters and arteriovenous grafts.

Take-Home Points

- Peripherally inserted central catheter placement imperils patients who will need future hemodialysis by eliminating veins that are critical for fistula construction.
- Peripherally inserted central catheters should always be placed only for valid indications, as outlined in the Michigan Appropriateness Guide for Intravenous Catheters.
- High-risk kidney patients should receive small-bore central venous catheters rather than peripherally inserted central catheters.
- Nephrology consultation may be useful in cases in which there is ambiguity about the risk of needing future dialysis.

Rita L. McGill, MD, MS
Associate Professor
Section of Nephrology
University of Chicago

Chicago, IL

References

1. Wetmore JB, Liu J, Li S, et al. The Healthy People 2020 objectives for kidney disease: how far have we come, and where do we need to go? Clin J Am Soc Nephrol. 2017;12:200-209. [go to PubMed]

2. Hoshal VL Jr. Total intravenous nutrition with peripherally inserted silicone elastomer central venous catheters. Arch Surg. 1975;110:644-646. [go to PubMed]

3. Parkinson R, Gandhi M, Harper J, Archibald C. Establishing an ultrasound guided peripherally inserted central catheter (PICC) insertion service. Clin Radiol. 1998;53:33-36. [go to PubMed]

4. Royer T. Nurse-driven interventional technology: a cost and benefit perspective. J Infus Nurs. 2001;24:326-331. [go to PubMed]

5. Christensen LD, Holst M, Bech LF, et al. Comparison of complications associated with peripherally inserted central catheters and Hickman catheters in patients with intestinal failure receiving home parenteral nutrition. Clin Nutr. 2016;35:912-917. [go to PubMed]

6. Suleyman G, Kenney R, Zervos MJ, Weinmann A. Safety and efficacy of outpatient parenteral antibiotic therapy in an academic infectious disease clinic. J Clin Pharm Ther. 2017;42:39-43. [go to PubMed]

7. Chopra V, Anand S, Krein SL, Chenoweth C, Saint S. Bloodstream infection, venous thrombosis, and peripherally inserted central catheters: reappraising the evidence. Am J Med. 2012;125:733-741. [go to PubMed]

8. McGill RL, Tsukahara T, Bhardwaj R, Kapetanos AT, Marcus RJ. Inpatient venous access practices: PICC culture and the kidney patient. J Vasc Access. 2015;16:206-210. [go to PubMed]

9. El Ters M, Schears GJ, Taler SJ, et al. Association between prior peripherally inserted central catheters and lack of functioning arteriovenous fistulas: a case-control study in hemodialysis patients. Am J Kidney Dis. 2012;60:601-608. [go to PubMed]

10. Ravani P, Quinn R, Oliver M, et al. Examining the association between hemodialysis access type and mortality: the role of access complications. Clin J Am Soc Nephrol. 2017;12:955-964. [go to PubMed]

11. McGill RL, Ruthazer R, Meyer KB, Miskulin DC, Weiner DE. Peripherally inserted central catheters and hemodialysis outcomes. Clin J Am Soc Nephrol. 2016;11:1434-1440. [go to PubMed]

12. Tangri N, Stevens LA, Griffith J, et al. A predictive model for progression of chronic kidney disease to kidney failure. JAMA. 2011;305:1553-1559. [go to PubMed]

13. Williams AW, Dwyer AC, Eddy AA, et al. Critical and honest conversations: the evidence behind the "Choosing Wisely" campaign recommendations by the American Society of Nephrology. Clin J Am Soc Nephrol. 2012;7:1664-1672. [go to PubMed]

14. Bhutani G, El Ters M, Kremers WK, et al. Evaluating safety of tunneled small bore central venous catheters in chronic kidney disease population: a quality improvement initiative. Hemodial Int. 2017;21:284-293. [go to PubMed]

15. Sharp R, Cummings M, Fielder A, Mikocka-Walus A, Grech C, Esterman A. The catheter to vein ration and rates of symptomatic venous thromboembolism in patients with a peripherally inserted central catheter (PICC): a prospective cohort study. Int J Nurs Stud. 2015;52:677-685. [go to PubMed]

16. Chick JFB, Reddy SN, Yam BL, Kobrin S, Trerotola SO. Institution of a hospital-based central venous access policy for peripheral vein preservation in patients with chronic kidney disease: a 12-year experience. J Vasc Interv Radiol. 2017;28:392-397. [go to PubMed]

17. Chopra V, Flanders SA, Saint S, et al; Michigan Appropriateness Guide for Intravenouse Catheters (MAGIC) Panel. The Michigan Appropriateness Guide for Intravenous Catheters (MAGIC): results from a multispecialty panel using the RAND/UCLA Appropriateness Method. Ann Intern Med. 2015;163(suppl 6):S1-S40. [go to PubMed]

18. Paje D, Conlon A, Kaatz S, et al. Patterns and predictors of short-term peripherally inserted central catheter use: a multicenter prospective cohort study. J Hosp Med. 2018;13:76-82. [go to PubMed]

Figures

Figure 1. Peripherally Inserted Central Catheter in Brachial Vein. (Illustration © 2018 Chris Gralapp.)

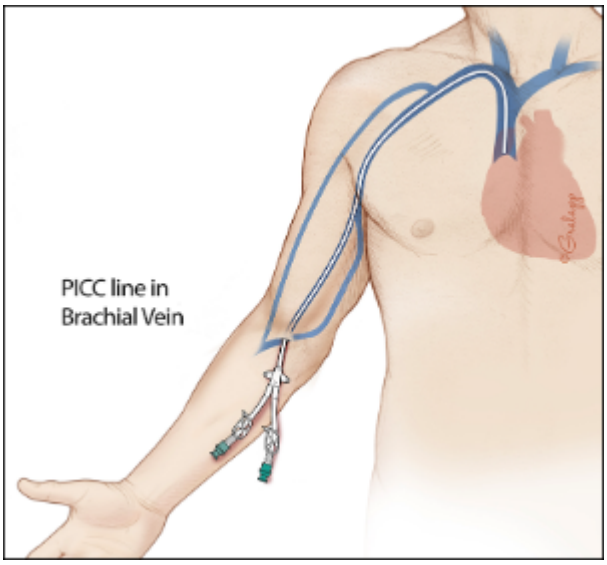

Figure 2. Arteriovenous Fistula. (Illustration © 2018 Chris Gralapp.)

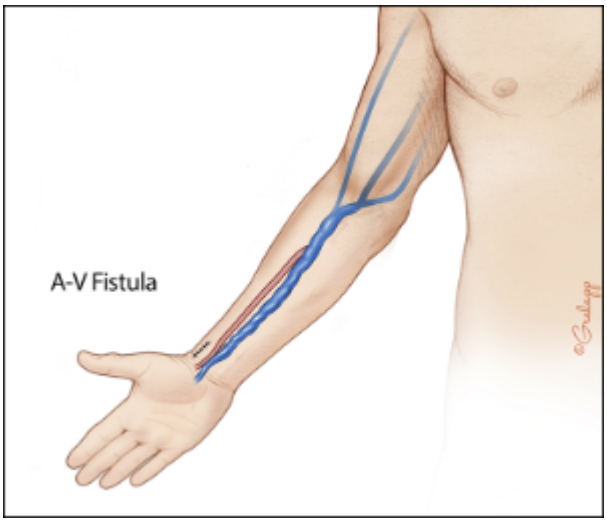

This project was funded under contract number 75Q80119C00004 from the Agency for Healthcare Research and Quality (AHRQ), U.S. Department of Health and Human Services. The authors are solely responsible for this report's contents, findings, and conclusions, which do not necessarily represent the views of AHRQ. Readers should not interpret any statement in this report as an official position of AHRQ or of the U.S. Department of Health and Human Services. None of the authors has any affiliation or financial involvement that conflicts with the material presented in this report. View AHRQ Disclaimers