

WebM&M

Morbidity and Mortality Rounds on the Web

Spotlight

Intraosseous Line Extravasation in a Pediatric Trauma Patient



Agency for Healthcare Research and Quality
Advancing Excellence in Health Care



Source and Credits

- This presentation is based on the April 2022 AHRQ WebM&M Spotlight Case
 - See the full article at <https://psnet.ahrq.gov/webmm>
 - CME credit is available
- Commentary by: David Barnes, MD and Joseph Yoon, MD
- AHRQ WebM&M Editors in Chief: Patrick Romano, MD, MPH and Deb Bakerjian, PhD, APRN, RN
 - Spotlight Editors: Patrick Romano, MD, MPH and Ulfat Shaikh, MD
 - Managing Editor: Meghan Weyrich, MPH

Objectives

At the conclusion of this educational activity, participants should be able to:

- Describe the role of intraosseous (IO) vascular access in resuscitation
- List the indications and contraindications for IO placement
- Describe the commonly used sites for IO line insertion
- Recognize complications associated with IO lines
- Appreciate the importance of anticipating procedural complications
- Identify signs and symptoms of acute compartment syndrome

INTRAOSSEROUS LINE EXTRAVASATION IN A PEDIATRIC TRAUMA PATIENT

This case highlights highlights complications associated with intraosseous (IO) lines, the importance of anticipating procedural complications, and methods to identify the signs and symptoms of acute compartment syndrome.

Case Details (1)

- An 18-month-old girl presented to the Emergency Department (ED) after being attacked by a dog and sustaining multiple penetrating injuries to her head and neck.
- On arrival to the ED, she was hypotensive, hypothermic, and obtunded. The trauma team identified early signs of hemorrhagic shock.
- After multiple unsuccessful attempts to establish intravenous access, an intraosseous (IO) line was placed in the patient's proximal left tibia to facilitate administration of fluids, blood products, vasopressors, and antibiotics.
- The patient was subsequently taken to the operating room for exploration and debridement of her injuries.
- She remained hypotensive requiring frequent boluses of crystalloid. Peripheral intravenous (IV) access was eventually obtained after which intraoperative use of the IO line was restricted to a low-rate fluid infusion.

Case Details (2)

- During surgery, her left lower extremity was palpated frequently and a pulse oximeter was placed distally on her left great toe to confirm continuous perfusion of the extremity.
- An hour into the operation, the anesthesiologist found her left calf to be warm and tense, presumably due to fluid extravasation from the IO line.
- The IO line was removed, and the Orthopedic Surgery service was consulted intraoperatively due to concern for acute compartment syndrome.

Case Details (3)

- At this point, the patient was hemodynamically stable with satisfactory peripheral IV access.
- The patient was transferred postoperatively to the pediatric intensive care unit (PICU) for close monitoring. Signs of compartment syndrome eventually resolved without any surgical intervention.

INTRAOSSEROUS LINE EXTRAVASATION IN A PEDIATRIC TRAUMA PATIENT

THE COMMENTARY

By David Barnes, MD and Joseph Yoon, MD

Summary

- This case demonstrates how a critically injured pediatric patient was effectively resuscitated with crystalloid and blood administered through an IO line when peripheral IV access was not available, highlighting the importance and utility of these vascular devices.
- The case reminds us that even straightforward procedures, like vascular access, are not without risk.
- The case also demonstrates how risks associated with medical interventions can be anticipated, monitored, and addressed to prevent irreparable harm.

BACKGROUND

Background (1)

- IO vascular access is a valuable clinical tool commonly utilized in the care of critically ill or injured adult and pediatric patients and is considered standard of care for resuscitation when peripheral IV access is delayed or not possible.
- IO access requires the operator to insert a hollow bore needle through bone cortex into the medullary space of the bone marrow.
- In contrast to modern peripheral IV catheters, which use a temporary metallic introducer needle to facilitate placement of a synthetic polymer catheter, IO devices use metallic needles attached to a plastic hub as the delivery vehicle. These needles remain embedded into the bone while the external plastic hub is secured to the skin.

Background (2)

- IO needles may be placed manually in the same fashion that a bone marrow biopsy is performed. They may also be placed using a spring-loaded bone injection gun.
- However, it is far more common that they are inserted with the aid of a battery-operated drill.
- While age-specific IO needles are available, and age-specific insertion techniques are recommended (e.g., bone injection gun versus EZ-IO®), both topics are beyond the scope of this commentary.

Background (3)

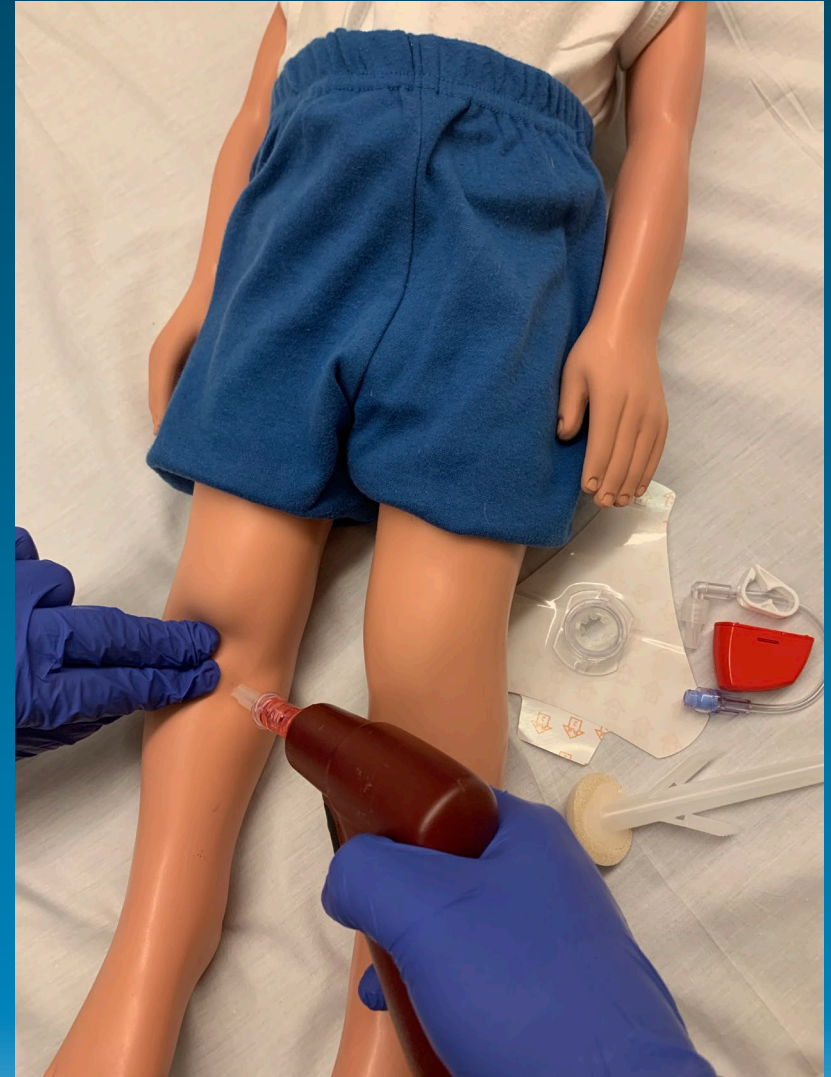- IO lines can be used to infuse medications and fluids, including blood products. They can also be used to draw blood for laboratory testing.
- Prompt vascular access with a peripheral IV or IO line is essential in the management of critically ill patients. In pediatric trauma patients, hypotension is a predictor of mortality, either from impending hemorrhagic shock or from traumatic brain injury.
- Although the preferred choice of fluid and the type and ratio of blood products for resuscitation of hemorrhagic shock have evolved, rapid volume expansion via vascular access is a primary consideration in all adult and pediatric shock resuscitation scenarios regardless of etiology (e.g., hypovolemic, distributive, cardiogenic).

Background (4)

- Observational studies suggest higher rates of return of spontaneous circulation and survival to hospital discharge in cardiac arrest when intravenous access is used, compared with IO access. However, these studies suffered from serious bias and provide low certainty of evidence due to confounding and selection factors related to delayed vascular access.
- Because IO access can be performed rapidly, it is an acceptable and valuable second option when IV access fails or is not feasible.
- Critical situations where IO access is commonly utilized include cardiopulmonary arrest, shock, sepsis, major traumatic injuries, extensive burns or edema, and status epilepticus.

Background (5)

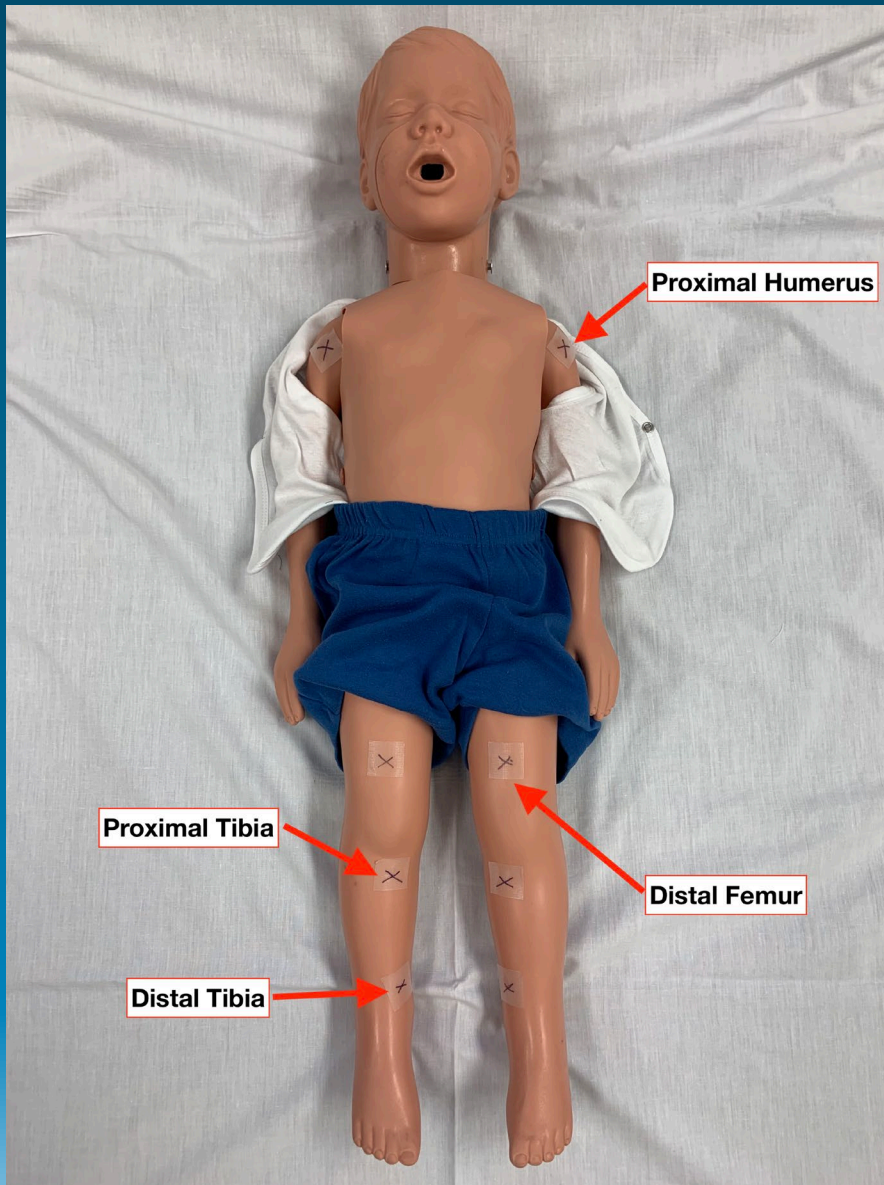
- IO insertion is easy to learn and quickly performed.
- Healthcare professionals (including MDs, RNs, and pre-hospital providers) can be taught to complete an IO insertion within 30 seconds.



Background (6)

- There are few contraindications to IO insertion.
 - IO needles should not be placed in an extremity with a long bone fracture, in an extremity with a vascular injury, or through skin with overlying infection or burn injury.
 - Additionally, patients with bone disease including osteogenesis imperfecta or osteoporosis who are at increased risk of iatrogenic fractures are poor candidates for IO placement.
 - An IO insertion site that was previously placed or attempted should not be reattempted because fluids may extravasate from these sites into surrounding tissues.

Background (7)



- Insertion points for IO lines include:
 - Proximal tibia
 - Proximal humerus
 - Sternum
 - Distal femur
 - Medial and lateral malleoli of the distal tibia

Background (8)

- In both adults and children, the *proximal tibia* is a popular insertion site for IO lines, especially during emergencies.
 - The proximal tibia is easily accessible in most patients and has an advantage over upper body sites by not interfering with chest compressions or ventilation during CPR.
 - The anterior compartment of the leg, adjacent to the proximal tibia, is the most common location for compartment syndrome in trauma.
 - However, whether proximal tibial IO devices have increased risk of compartment syndrome, relative to other sites, is unknown.

Background (9)

- The *proximal humerus* is another common site for IO line placement.
 - Some authors recommend this site over the proximal tibia because of its proximity to the central circulation and higher infusion flow rates for large volume resuscitation.
 - One animal study compared infusion rates from various IO sites to a peripheral IV site utilizing normovolemic piglets. Compared to a 22g peripheral IV, through which crystalloid can be infused at 13.1 mL/min under gravity, flow rates were 11.1 mL/min through a humeral IO line and 4.3 mL/min through a tibial IO line, respectively.
 - Other potential advantages of humeral IO placement include decreased pain, higher first attempt success rate, and utility in patients with lower extremity injuries.

Background (10)

- Early research into the use of IO lines focused on access through the *sternum* due to its high composition of red marrow, which was thought to be necessary for successful infusion.
 - Advantages include easy accessibility and proximity to the central venous circulation.
 - However, sternal infusion in children less than five years of age is no longer recommended because of poor flow given the small size of the marrow cavity and the higher risk of great vessel injury.
- The *distal femur* has been used extensively in pediatric IO infusions but not in adults. Though successfully used in both neonates and infants due to its large epiphysis, the distal femur is less accessible in adults due to overlying muscle.

Background (11)

- Lastly, both the medial and lateral malleoli of the distal tibia have been used for IO infusion in adults and children, with preference for the medial malleolus.
- Advantages of IO insertion at the distal tibia include:
 - A thinner bone cortex compared to the proximal tibia, which allows for easier insertion.
 - Compartment syndrome and infectious complications are rare, with few case reports in the literature.
- Other distal long bone sites, such as the radius, ulna, and fibula, are not suitable sites for IO infusion.

Background (12)

- Though complications involving insertion of IO lines are rare, significant morbidity can occur if the catheter is not inserted correctly or not removed promptly once a complication arises.
 - In one study, local edema and infiltration occurred in 12% of patients, and complications were more common after 24 hours.
 - Compartment syndrome is a rare but serious, limb-threatening complication associated with IO line placement as blood, fluids, and drugs administered through the IO may extravasate into the surrounding soft tissues.
 - Other complications include osteomyelitis, skin abscess, bone fracture, and cellulitis, although all of these are uncommon.

COMPARTMENT SYNDROME

Compartment Syndrome (1)

- Compartment syndrome is a true orthopedic emergency that can result from several different processes including traumatic and non-traumatic etiologies and may occur in any of the over 40 anatomical compartments in the human body.
 - Anatomical compartments are comprised of rigid, unyielding fascia and bone that contain compressible muscles, nerves, and blood vessels.

Compartment Syndrome (2)

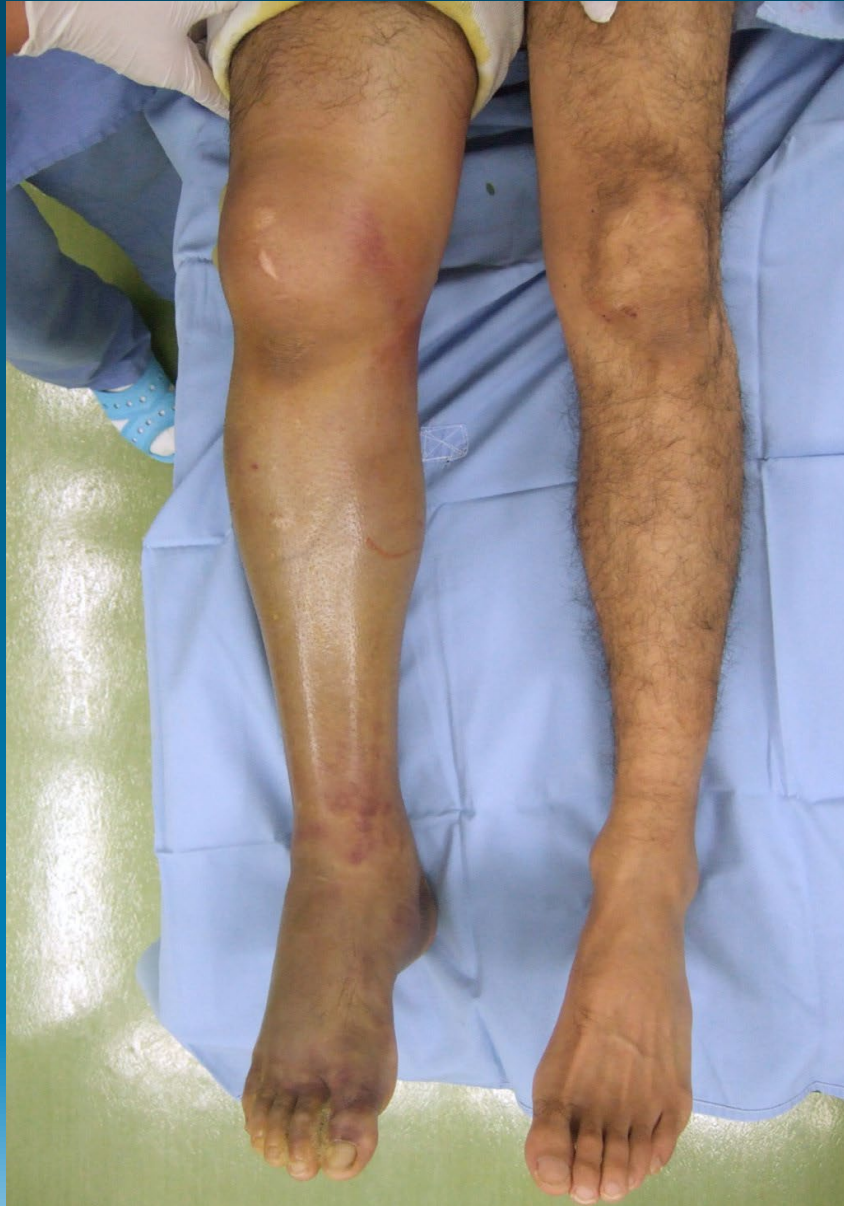

Image is from Takeda S, Tatebe M, Sakai A, Hirata H. Two cases of unidentified acute compartment syndrome. *BMJ Case Rep.* 2018;2018:bcr2017222377. Published 2018 Apr 1. doi:10.1136/bcr-2017-222377 (Figure 4)

Compartment Syndrome (3)

- In a study of 164 patients with acute compartment syndrome, 69% had an associated fracture and nearly half of the cases were related to the tibial shaft.
 - Most patients in this case series were men under 35 years of age, reflecting the high incidence of trauma in this population.
 - However, any addition of fluid—edema, hemorrhage, or crystalloid solutions—into the fascial compartment can abruptly raise intra-compartmental pressure threatening limb function and viability.
 - Although it is more likely in the pediatric population, extramedullary fluid extravasation from an IO line has been associated with compartment syndrome in both children and adults.

Compartment Syndrome (4)

- The ischemic threshold of muscle is reached when pressure within the compartment is elevated to 20 mm Hg below the diastolic pressure or 30 mm Hg below the mean arterial blood pressure.
- Elevated compartment pressure leads initially to venous congestion, then impaired arterial perfusion, and ultimately limb ischemia.
- If prolonged, irreversible damage to muscles, nerves, and blood vessels contained within the compartment results in necrosis, scarring, and contractures. Limb viability is threatened and amputation is necessary in some cases.

Compartment Syndrome (5)

- Because of the risk of extravasation inherent to IO lines, it is critical that clinicians and care teams anticipate this complication and closely monitor for signs of it while an IO line remains in use.
- **Early recognition is critical to prevent irreversible damage.**
- Compartment syndrome is a clinical diagnosis and patients' reported symptoms are the earliest indicators, including (in alert patients):
 - Pain at rest, often characterized as out of proportion to exam,
 - Pain with passive stretch of the involved muscle,
 - Motor weakness, and
 - Loss of sensation in the neuronal distribution of the involved compartment.
- Clinical signs of compartment syndrome include tenseness or firmness of the involved compartment.

Compartment Syndrome (6)

- Classically, the “5 Ps” (variably referred to as the “6 Ps”), describing the cardinal signs and symptoms of limb ischemia, have been used in the assessment of compartment syndrome: **Pain**, **Paresthesia**, **Pallor**, **Paralysis**, and **Pulselessness** (the 6th P is **Poikylothermia**).
 - Unfortunately, these findings are unreliable in acute limb ischemia as well as compartment syndrome.
 - Of the six signs and symptoms, only pain is a reliable sign of compartment syndrome.
 - Pain that is described as burning, delayed onset, increasing in severity, or worsened by passive stretch of the compartment should prompt investigation for possible compartment syndrome

Compartment Syndrome (7)

- Identifying compartment syndrome early can be particularly difficult in children due to inherent limitations in their ability to communicate.
- One author has proposed using the “3 As” to monitor for compartment syndrome in young children: increased Analgesic requirement, Anxiety, and Agitation.
- Increased analgesic requirement was found to be a sensitive and reliable indicator of early compartment syndrome in children.

Compartment Syndrome (8)

- Reliance on symptoms of compartment syndrome is difficult in a child who is obtunded or cognitively impaired, and nearly impossible in a child who is intubated and sedated.
- In these circumstances, a high degree of suspicion is necessary. While not always necessary or practical, continuous monitoring of compartment pressures has been utilized to confirm or exclude compartment syndrome.
- Threshold pressure values for fasciotomy have been defined in adults but similar cutoff values are unreliable and rarely used in pediatrics due to differences in normal resting compartment pressures in children.

Compartment Syndrome (9)

- Near-infrared spectroscopy, which uses various light absorption properties of oxygenated hemoglobin like that used in pulse oximetry, has been proposed as an objective and non-invasive tool for the diagnosis of compartment syndrome.
- Although it was used in the present case, pulse oximetry of the limb is not a reliable tool to monitor for compartment syndrome.
- As in adults, compartment syndrome remains a clinical diagnosis in children.

Compartment Syndrome (10)

- IO-related compartment syndrome has been attributed to technical errors during needle insertion. These errors include:
 - Incomplete penetration of the bone cortex
 - Penetration of the needle through the posterior cortex
 - Extravasation through a previous IO puncture site
 - Extravasation through the foramina of nutrient vessels

Compartment Syndrome (11)

- To avoid these errors, operators should:
 - 1) Use a needle strong enough to penetrate bone and withstand bending forces
 - 2) Splint the target limb to avoid disturbing the IO needle
 - 3) Minimize patient transport with an IO line in place
 - 4) Avoid insertion into fractured bone
 - 5) Avoid repeated penetration attempts into the same bone cortex
- In an animal model that attempted to eliminate these technical errors, compartment pressures increased in proportion to the volume of fluid infused, suggesting compartment syndrome may develop despite sound operator technique.
- Therefore, close attention to fluid dose and infusion rate is another best practice to prevent IO-related compartment syndrome.

APPROACH TO IMPROVING SAFETY

Approach to Improving Patient Safety (1)

- This case demonstrates how an unstable pediatric patient with traumatic injuries was effectively managed both acutely in the ED and definitively in the operating room.

Approach to Improving Patient Safety (2)

- Once a patient is hemodynamically stable, definitive care of injuries can proceed.
- In the present case, the patient was promptly transferred to the OR for surgical exploration, debridement, and possible closure of her traumatic wounds, but because the patient was critically ill, removal of the IO line prior to transport to the OR was not appropriate.
- An intravenous line (or lines) should be established, under more controlled conditions, to provide definitive vascular access while fluids are being infused through the IO line.
- Once IV access is obtained, the IO line should be discontinued. It is recommended that any IO line be removed within 24 hours after placement to minimize complications

Approach to Improving Patient Safety (3)

- When an IO line is required, care must be taken to ensure careful insertion and avoid overly aggressive fluid infusion.
- Clinicians should exam the target limb frequently.
- At minimum, this should include a neurovascular exam and palpation of the limb's compartment for the presence of tensesness, which may indicate elevated compartment pressure.

Approach to Improving Patient Safety (4)

- If early signs of compartment syndrome are detected, infusion through the IO line should be discontinued once an IV line is placed, and an orthopedic surgeon should be consulted for further management, which may include fasciotomy.
- Fortunately, the anesthesiologist in the present case proactively monitored for signs of compartment syndrome leading to early diagnosis, abrupt discontinuation of the IO line, avoidance of surgical intervention, and an excellent clinical outcome for the patient.

TAKE HOME POINTS

Take-Home Points (1)

- Prompt vascular access is a time-sensitive priority for hemodynamically unstable patients.
- Ideally, two large bore peripheral IV lines should be placed in unstable patients. Intraosseous lines should be utilized when peripheral intravenous lines cannot be obtained quickly.
- Compartment syndrome is a rare but serious complication associated with IO lines. Proper insertion technique and avoiding aggressive rates of fluid infusion can reduce the risk of compartment syndrome.
- Compartment syndrome is a clinical diagnosis. The “3 As” (increased Analgesic requirement, Anxiety, and Agitation) provide a useful tool to assess for compartment syndrome in pediatric patients.
- The extremity in which an IO line is placed should be frequently monitored, especially with prolonged use.

Take-Home Points (2)

- If extremity compartment syndrome is suspected, fluid administration through any vascular device in that extremity—including an IO line—should be promptly discontinued while alternative vascular access is secured.
- An orthopedic surgeon should be consulted when extremity compartment syndrome is suspected.
- Many procedures and medical interventions are associated with known risks and complications, including compartment syndrome.
- Anticipating these risks and monitoring for their presence can reduce or eliminate harm.

REFERENCES

References

1. Merchant RM, Topjian AA, Panchal AR, et al. Part 1: Executive Summary: 2020 American Heart Association Guidelines for Cardiopulmonary Resuscitation and Emergency Cardiovascular Care. *Circulation* 2020;142(16_suppl_2):S337–57.
2. Dornhofer P, Kellar JZ. Intraosseous Vascular Access. *StatPearls* 2021;
3. Mendelson J. Emergency Department Management of Pediatric Shock. *Emerg Med Clin N Am* 2018;36(2):427–40.
4. White JRM, Farukhi Z, Bull C, et al. Predictors of outcome in severely head-injured children. *Crit Care Med* 2001;29(3):534–40.
5. Granfeldt A, Avis SR, Lind PC, et al. Intravenous vs. intraosseous administration of drugs during cardiac arrest: A systematic review. *Resuscitation* 2020;149:150–7.
6. Luck RP, Haines C, Mull CC. Intraosseous Access. *J Emerg Medicine* 2010;39(4):468–75.
7. Torres F, Galán MD, Alonso M del M, Suárez R, Camacho C, Almagro V. Intraosseous Access EZ-IO in a Prehospital Emergency Service. *J Emerg Nurs* 2013;39(5):511–4.
8. Molin R, Hallas P, Brabrand M, Schmidt TA. Preferred anatomic site for intraosseous infusion in Danish emergency departments. *Scand J Trauma Resusc Emerg Medicine* 2010;18(Suppl 1):P26–P26.
9. Paxton JH. Intraosseous vascular access: A review. *Trauma* 2012;14(3):195–232.
10. Torlincasi AM, Lopez RA, Waseem M. Acute Compartment Syndrome. *StatPearls* 2021;
11. Lairer J, Bebart V, Lairer K, et al. A Comparison of Proximal Tibia, Distal Femur, and Proximal Humerus Infusion Rates Using the EZ-IO Intraosseous Device on the Adult Swine (*Sus scrofa*) Model. *Prehosp Emerg Care* 2013;17(2):280–4.
12. Warren DW, Kisson N, Sommerauer JF, Rieder MJ. Comparison of fluid infusion rates among peripheral intravenous and humerus, femur, malleolus, and tibial intraosseous sites in normovolemic and hypovolemic piglets. *Ann Emerg Med* 1993;22(2):183–6.
13. Tocantins LM, O'NEILL JF, Price AH. Infusion of blood and other fluids via the bone marrow in traumatic shock and other forms of peripheral circulatory failure. *Ann Surg* 1941;114(6):1085–92.
14. Jaimovich DG, Kecskes S. Intraosseous infusion: A re-discovered procedure as an alternative for pediatric vascular access. *Indian J Pediatrics* 1991;58(3):329–34.
15. Waisman M, Waisman D. Bone Marrow Infusion in Adults. *J Trauma Inj Infect Critical Care* 1997;42(2):288-293.

References

16. Rosetti VA, Thompson BM, Miller J, Mateer JR, Aprahamian C. Intraosseous infusion: An alternative route of pediatric intravascular access. *Ann Emerg Med* 1985;14(9):885–8.
17. Moscati R, Moore GP. Compartment syndrome with resultant amputation following intraosseous infusion. *Am J Emerg Medicine* 1990;8(5):470–1.
18. Simmons CM, Johnson NE, Perkin RM, Stralen D van. Intraosseous Extravasation Complication Reports. *Ann Emerg Med* 1994;23(2):363–6.
19. Fiser DH. Intraosseous Infusion. *New Engl J Medicine* 1990;322(22):1579–81.
20. Newton EJ, Love J. Acute Complications of Extremity Trauma. *Emerg Med Clin N Am* 2007;25(3):751–61.
21. McQueen MM, Gaston P, Court-Brown CM. Acute compartment syndrome. *J Bone Jt Surg* 2000;82(2):200–3.
22. Hosseinzadeh P, Hayes CB. Compartment Syndrome in Children. *Orthop Clin N Am* 2016;47(3):579–87.
23. Olson SA, Glasgow RR. Acute compartment syndrome in lower extremity musculoskeletal trauma. *J Am Acad Orthop Surg* 2005;13(7):436–44.
24. Taylor CC, Clarke NMP. Amputation and intraosseous access in infants. *Bmj* 2011;342(may27 1):d2778.
25. Schmidt AH. Acute Compartment Syndrome. *Orthop Clin N Am* 2016;47(3):517–25.
26. Bae DS, Kadiyala RK, Waters PM. Acute compartment syndrome in children: contemporary diagnosis, treatment, and outcome. *J Pediatric Orthop* 2001;21(5):680–8.
27. Schmidt AH. Acute compartment syndrome. *Inj* 2017;48:S22–5.
28. Shuler MS, Reisman WM, Kinsey TL, et al. Correlation Between Muscle Oxygenation and Compartment Pressures in Acute Compartment Syndrome of the Leg. *J Bone Jt Surg* 2010;92(4):863–70.
29. Tobias JD, Hoernschemeyer DG. Near-Infrared Spectroscopy Identifies Compartment Syndrome in an Infant. *J Pediatr Orthoped* 2007;27(3):311–3.
30. Mars M, Hadley GP. Failure of pulse oximetry in the assessment of raised limb intracompartmental pressure. *Inj* 1994;25(6):379–81.

References

31. Günel I, Köse N, Gürer D. Compartment syndrome after intraosseous infusion: An experimental study in dogs. *J Pediatr Surg* 1996;31(11):1491–3.
32. Burke T, Kehl DK. Intraosseous infusion in infants. Case report of a complication. *J Bone Jt Surg* 1993;75(3):428–9.
33. Spivey WH. Intraosseous infusions. *J Pediatrics* 1987;111(5):639–43.
34. Galpin RD, Kronick JB, Willis RB, Frewen TC. Bilateral Lower Extremity Compartment Syndromes Secondary to Intraosseous Fluid Resuscitation. *J Pediatr Orthoped* 1991;11(6):773–6.
35. Ribeiro JA, Price CT, Jr. DRK. Compartment Syndrome of the Lower Extremity after Intraosseous Infusion of Fluid. *Journal of Bone and Joint Surgery* 1991;75-A(3):430–3.
36. Rimar S, Westry JA, Rodriguez RL. Compartment Syndrome in an Infant Following Emergency Intraosseous Infusion. *Clin Pediatr* 1988;27(5):259–60.
37. Whitesides TE, Haney TC, Morimoto K, Harada H. Tissue Pressure Measurements as a Determinant for the Need of Fasciotomy. *Clin Orthop Relat R* 1975;113(NA:):43–51.
38. Patil V, Shetmahajan M. Massive transfusion and massive transfusion protocol. *Indian J Anaesth* 2014;58(5):590–5.